



PATIENT PRESENTING CLINICAL SIGNS

Kumo Henritzky
History: Grade 3/6 heart murmur. Assess prior to dental.
-Current medications: NeoPolyDex.

SPECIES ECHOCARDIOGRAM FINDINGS

Canine
Breed: Chihuahua
SEX: Male Neutered
AGE: 14 years
WEIGHT: 4.9lbs
The tricuspid valve appears normal with trace tricuspid regurgitation. Normal velocity. Normal right atrial and ventricular diameter and morphology indicating no overt evidence of pulmonary arterial hypertension. The pulmonic and aortic valves are normal in morphology and mobility. Normal pulmonic and aortic outflow velocities with laminar flow. Trace aortic and no pulmonic insufficiency. No pericardial or pleural effusion noted. No obvious cardiac masses.

SEX CARDIAC CHART

CANINE CARDIAC PARAMETERS	MR VMAX (m/s)	TR VMAX (m/s)	LA/AO (Boon method)	LA/AO (Heart Base; Swe)	FS (%)	EF (%)	EPSS (cm)
NORMAL PARAMETER	4.5-5.5	<2.7	1.3	<1.6	28-40	40-100	<0.6
PATIENT	5.9	2.2	NM	1.3	50	84	0.62
CANINE CARDIAC PARAMETER RS	HR (BP M)	AV VMAX (m/s)	PV MAX (m/s)	BODY WEIGHT (kg)	LA 2D short axis Base view (cm)	LVIDd Avg; 2D and m-mode short axis (cm)	LVIDs Avg; 2D and m-mode short axis (cm)
NORMAL PARAMETER	50-100	0.7-1.7	0.7-1.6	BELOW	BELOW	BELOW	BELOW
PATIENT	167	NM	1.5	2.2	1.4	2.1	1.0
*Normal chamber parameters expressed as a mean value				3	1.27	2.46	1.36
BODY WEIGHT DEPENDENT PARAMETERS				5	1.40	2.74	1.60
*Note: All measurements based upon multi-modal images and methods. An average value is reported.				10	1.50	3.27	2.06
				15	1.83	3.71	2.43
				20	2.02	4.14	2.80
				25	2.18	4.48	3.10
				30	2.33	4.83	3.39
				35	2.48	5.17	3.69
				40	2.62	5.48	3.96
				50	2.88	6.07	4.46

INTERPRETATION OF THE FINDINGS & FURTHER RECOMMENDATIONS

Chronic degenerative valve disease causing mild mitral and trace tricuspid regurgitation. Lack of left atrial enlargement indicates the current risk for complication is low. A small aortic insufficiency is noted, and a baseline BP is recommended. No concurrent issues such as systolic dysfunction or pulmonary hypertension are noted in this study.

INVOICE

30552

DATE

5/2/23

INTERPRETED BY
Maggie Machen
Lamy, DVM, DACVIM
(Cardiology)

IMAGING PERFORMED BY

Rebekah Jakum, CVT
ARDMS/RVT

HOSPITAL NAME

Maple Hills VH

REFERRING VET

Dr. Eckman

Adapted from June Boon, Veterinary Echocardiography, 1998
Rishniw M and Hollis NE, J Vet Intern Med 2000; 14:429-435
Hansson et al, Vet Rad and Ultrasound 2002
Bonagura et al. Echocardiography: principles of interpretation, Vet Clin North Am 15:1177, 1995



PATIENT

Kumo Henritzky

Anesthetic risk is considered mild. Cardiac protective drug choices (opioid/benzodiazepine premedication, propofol or alfaxalone induction, isoflurane gas) are recommended. Pre-oxygenate for 5-10 minutes prior to induction. Monitor for arrhythmias, hypotension, and hypoxia both intra and post-operatively and intervene as necessary. Mild IV fluid restriction is recommended to avoid fluid overload. Avoid heart rate stimulating drugs such as atropine unless clinically indicated.

SPECIES

Canine

Recommend conservative monitoring with a recheck echocardiogram in 6-12 months, sooner if any development of clinical signs.

BREED

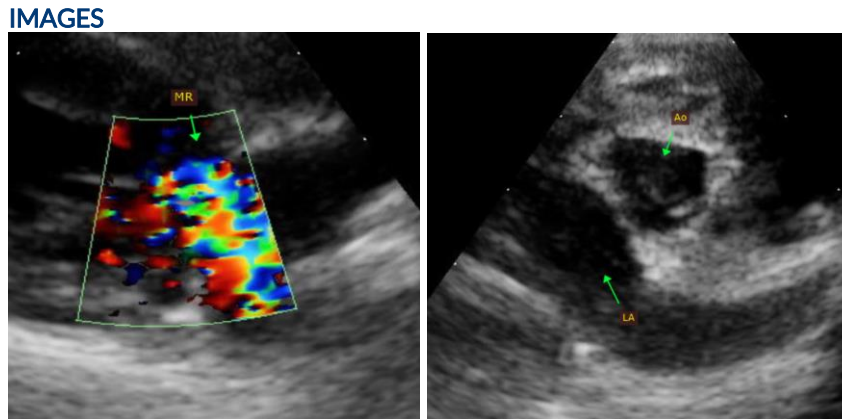
Chihuahua

SEX

Male Neutered

AGE

14 years



WEIGHT

4.9lbs

The information and recommendations provided are based on the images presented by the referring veterinarian. No evaluation can be communicated regarding pathology that was not visible in the image/video clips provided.

INTERPRETED BY

Maggie Machen
Lamy, DVM, DACVIM
(Cardiology)

Thank you for this referral. If the clinical or image interpretation does not parallel your findings or if I can be of any further assistance, please contact me.

Maggie Machen Lamy, DVM
Diplomate of the American College of Veterinary Internal Medicine (Cardiology)
info@sonopath.com

IMAGING PERFORMED BY

Rebekah Jakum, CVT
ARDMS/RVT

HOSPITAL NAME

Maple Hills VH

REFERRING VET

Dr. Eckman

INVOICE

30552

DATE

5/2/23